

FEMALE-TO-MALE UROGENITAL RECONSTRUCTION: “THE CENTURION PROCEDURE”

BY TEX MCFADEN, D.O.
DIRECTOR, RESEARCH & CLINICAL TRIALS
AMERICAN INSTITUTE FOR PLASTIC SURGERY

Over the years, Peter Raphael, M.D. has worked with patients from all walks of life. While their needs have varied, their goals have centered on finding a way to make their outer appearance reflect their inner self-image.

Along the way, gender dysphoria patients making the female-to-male transition approached Dr. Raphael seeking an improvement over the existing metaoidioplasty and phalloplasty procedures. The dilemma of devising such a procedure centered on how to create a penis that might have the potential to retain sensation and some level of function. Medical literature reviews revealed the failures of various types of grafts, including poor aesthetics, the potential for high rates of morbidity, necrosis, sepsis, and permanent erectile dysfunction.

In his efforts to achieve such an improvement, Dr. Raphael continues to refine the Centurion and works in conjunction with gynecologic oncologist Alan Munoz, M.D. in this endeavor. An expert in his field, Dr. Munoz’ input has been invaluable in implementing Dr. Raphael’s Centurion innovations, particularly with their innovation of a new vaginoplasty technique.

Dr. Raphael’s success and patient satisfaction has been enhanced by the continuity of care and personnel who work with the transgender/gender dysphoria (TG/GD) patients during the female-to-male (FTM) process. Patients can expect knowledgeable consultants and staff to expertly assist them with their inquiries, consultations, surgery scheduling, and finance options, as well as a fine anesthesia department to diligently monitor them from the pre-op area, through surgery, and into the recovery room.

The American Institute for Plastic Surgery and The Summit Surgery Center constantly strive to provide all patients with a solid core of compassionate, competent medical staff who will answer their every question, assist them in preparing for their surgery, and follow their care and progress from initial contact until long beyond final recovery.

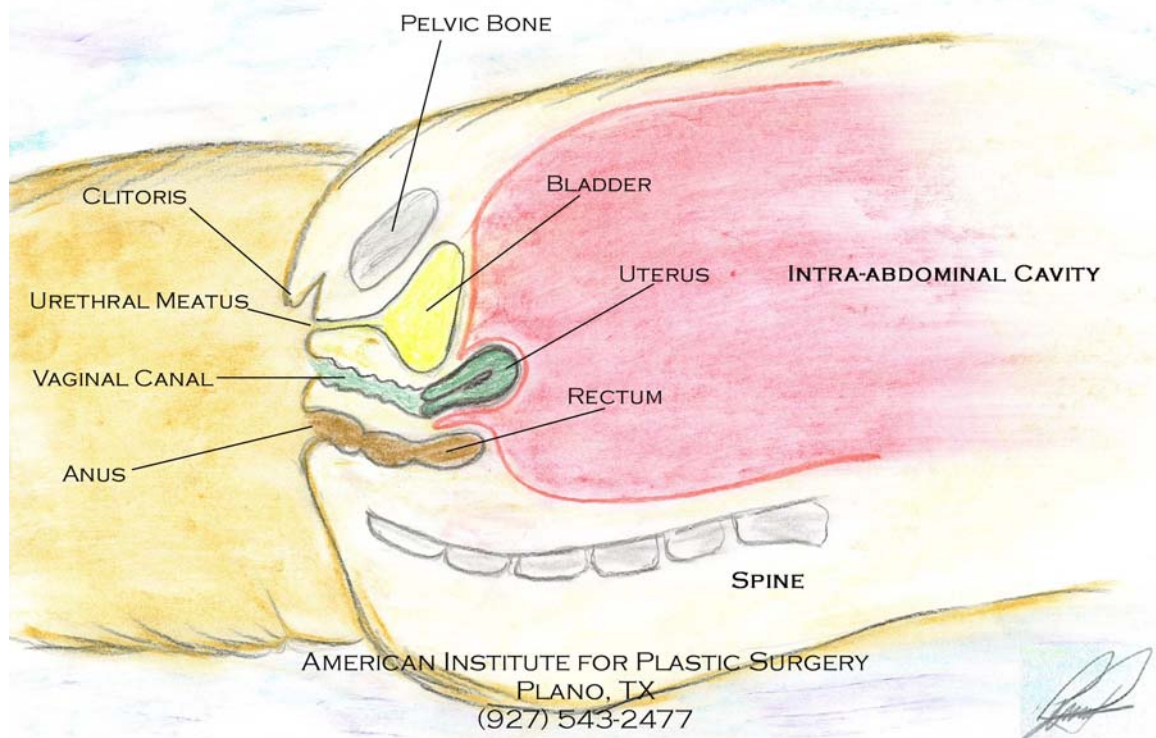
The Centurion Procedure

The first Centurion procedure was performed in June 2002 and is typically performed in conjunction with a vaginoplasty and a hysterectomy with bilateral salphingo-oophorectomy. The hysterectomy with bilateral salphingo-oophorectomy and a vaginoplasty requires approximately 1.5 hours to perform. The Centurion procedure takes approximately 2.5 hours.

Every patient's anatomy varies, thus surgery time can also vary. The most important, yet variable, component in constructing a neo-phallus is the amount and type of available tissue. When less tissue is available to recruit for constructing the various structures, the surgery will naturally take longer to complete. Recovery times after surgery will vary, but patients should expect to be limited in their physical activities during the initial two to three weeks and gradually increase over time. All of the restrictions are thoroughly discussed with each patient by Dr. Raphael and his staff on an ongoing basis.

For visual reference, here is an illustration of the normal female anatomy prior to surgery.

PRE-SURGICAL NORMAL FEMALE ANATOMY

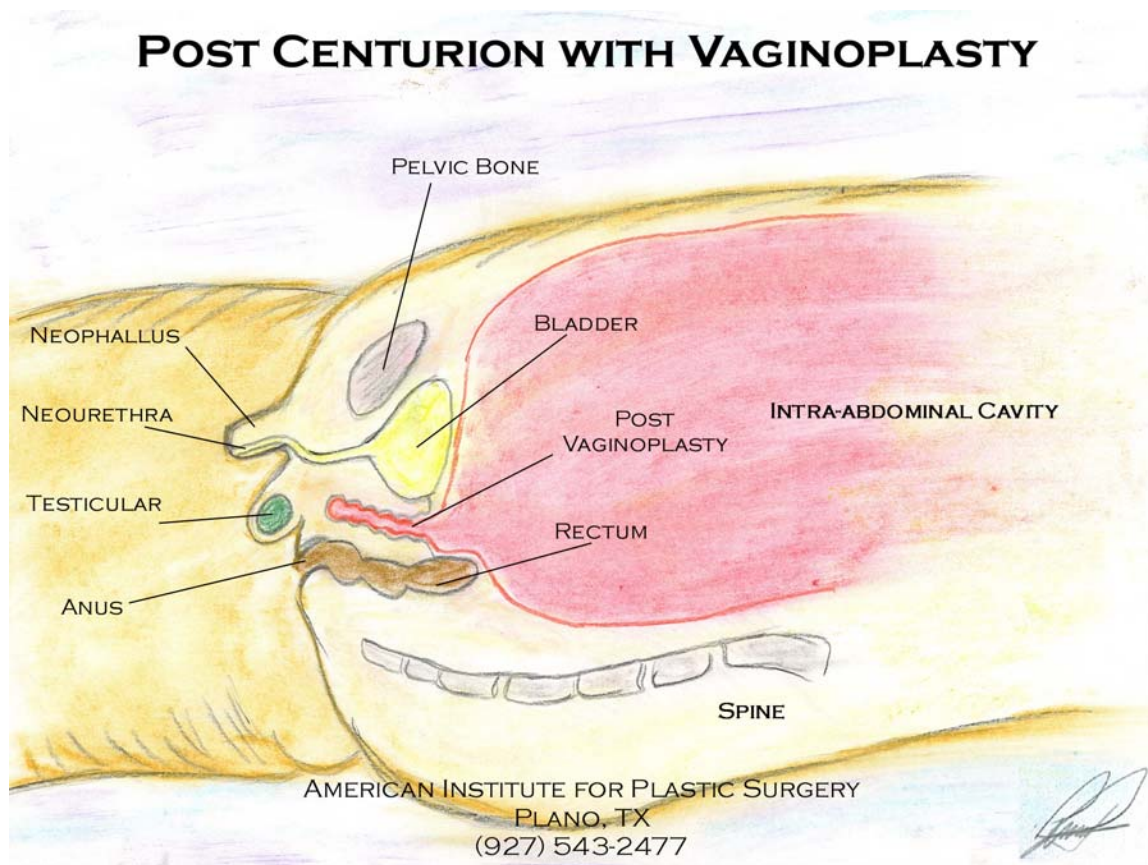


If the patient requires a hysterectomy and bilateral salphingo-oophorectomy, then Drs. Raphael and Munoz first step is to perform an abdominal hysterectomy prior to proceeding with the vaginoplasty. If no hysterectomy is required, the surgeons will enter the abdomen through the same incision site previously used for the patient's hysterectomy and perform the vaginoplasty.

Dr. Raphael's vaginoplasty technique is his innovative approach, conceived and refined with Dr. Munoz' input, to safely deal with the native vaginal tissue. The traditional vaginectomy carries a high morbidity rate due to risk extensive hemorrhaging and of injury, such as perforation, to any number of nearby critical organs, including the abdomen, bladder, bowel, and rectum. Considering these risks and noting the importance

of vaginal tissue with regards to proper bladder function, the surgeons brainstormed this new technique to significantly reduce morbidity and to maintain proper bladder function.

The vaginoplasty effectively closes the vagina in a safer and more efficient manner by opening the vagina from above in the abdomen and then closing it at the lower native opening. This essentially reverses the original configuration where the vagina is naturally open at the bottom and closed at the top, at the abdomen wall. This eliminates the potentially risky dissection of the vaginal tissue required with a vaginectomy and leaves the crucial tissue in place to continue to regulate bladder function. The vaginoplasty essentially creates a new pocket at the bottom of the abdomen. Any fluids secreted by the vaginal tissue will simply be absorbed, processed and dealt with/excreted by the body in typical fashion as are any fluids arising anywhere in the human body. So that you might visualize the vaginoplasty, Dr. Raphael's illustration of the post-operative Centurion with vaginoplasty is provided below.



Once the vaginoplasty is complete and the abdominal incision is closed, Dr. Raphael and his surgical team continue the procedure by releasing the clitoris at the chordee. The suspensory ligaments are left intact to provide support. The erectile nature of clitoris will provide the basis of the neo-phallus erection post-operatively. The round ligaments are distally (meaning farthest from the body) dissected free from the labia majora and then further back to an area just above the clitoris/neo-phallus (the “mons”). The freed proximal ends of the round ligaments are brought through tunnels in the tissue along each

side of the released-clitoris/neo-phallus. Then, they will be joined just below the “head” of the clitoris, thus filling the length of the shaft and the head of the neo-phallus. The round ligaments, although not erectile in nature, provide girth along the length of the shaft of the neo-phallus. The round ligaments will then be sutured in place along the shaft and further back into the “mons” areas above the base of the neo-phallus. This will further stabilize the shaft and the base of the neo-phallus. Finally, in the “mons” area, the fascia overlaying the pubic bones is gathered and sutured together. Not only will this help support and stabilize the neo-phallus, but will help prevent retraction of the neo-phallus. Retraction is a natural tendency, especially in overweight patients, of the tissues until they are “re-trained” over time through stretching and use.

The labia majora will become the scrotal sac. Pockets will be created in each labia majora, utilizing the vacant space left after the round ligaments were dissected out. These two pockets will accommodate the individually customized solid silicone testicular implants and will later be conjoined to form an anatomically and aesthetically correct scrotal sac. Where the round ligaments once held in the labia majora up, their absence now will allow the tissue to stretch out and down over time such that in about three months time, a fairly typical scrotal sac will be evident upon inspection.

The challenging portion of any Centurion is creating the neo-urethra. The neo-urethra begins at the native urethra opening, typically consists of three conjoined flaps, and ends at the head of the neo-phallus. The availability of tissue to create these flaps is the limiting factor in the number and length of the flaps, and thus the overall length of the new urethral extension. The more tissue that can be recruited for the neo-urethra, the longer the neo-urethra can be and thus the longer the neo-phallus.

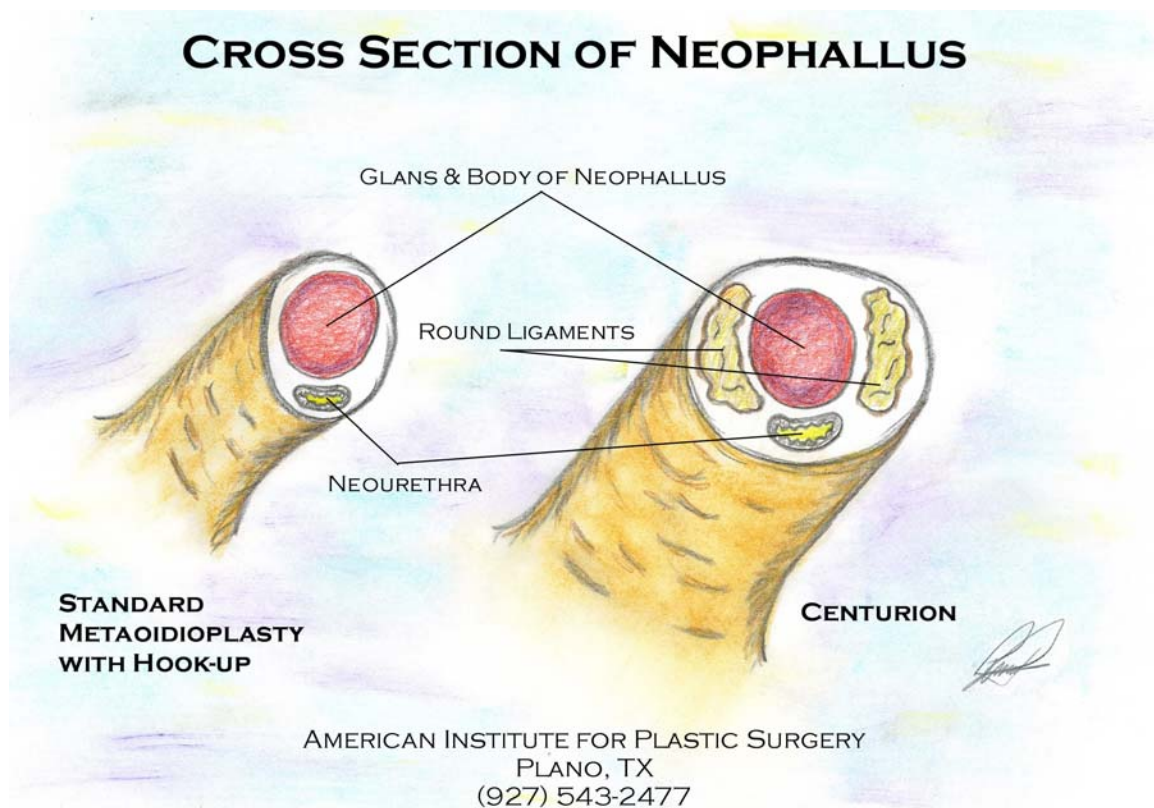
The flaps that are recruited are wrapped around the foley catheter tube, which was placed prior to the start of the Centurion procedure. Each flap is carefully joined, beginning at the native urethra, until all flaps have been joined around the foley catheter and to each other. Thus, the neo-urethra fully encloses the catheter, which will serve as a pseudo-stent while the neo-urethra heals and the flaps integrate to form one continuous tube. To further support the neo-urethra and its new direction upward through the neo-phallus, muscle tissue from both side of the immediate area around the base of the neo-urethra are gathered and sutured together. This, in effect, helps to shore up or strengthen the repairs made in the area, such as the closure of the vaginal opening, by holding the strongest tissue (the muscle) in close proximity thereby helping prevent overstretching or tearing of the more fragile or repaired tissues in that area.

At this stage, all that essentially remains is closure. Beginning with the tissues beneath the superficial skin, the two halves of the scrotal sac are joined and sutured together, as is the shaft of the neo-phallus. Then, superficial skin closure is performed, including the original vaginal opening, the scrotal sac, and the shaft of the neo-phallus.

The patient can expect to have the foley catheter for approximately two weeks before it may be removed at the surgeon’s discretion.

To date, the main issues with this procedure have been occasional testicular implant extrusion through the suture site, which relates to available tissue and the health and thickness of the tissue, and neo-urethral stricture or fistula, which may require routine dilation for a period of time until the neo-urethral tissues adapt to their new function. Dr. Raphael has recently begun trying another innovation aimed at reducing the possibility of neo-urethral stricture by utilizing a “muscle wrap” in the neo-phallus. This new technique is currently being evaluated in surgical patients. Any necessary revision is typically done six months after the initial procedure.

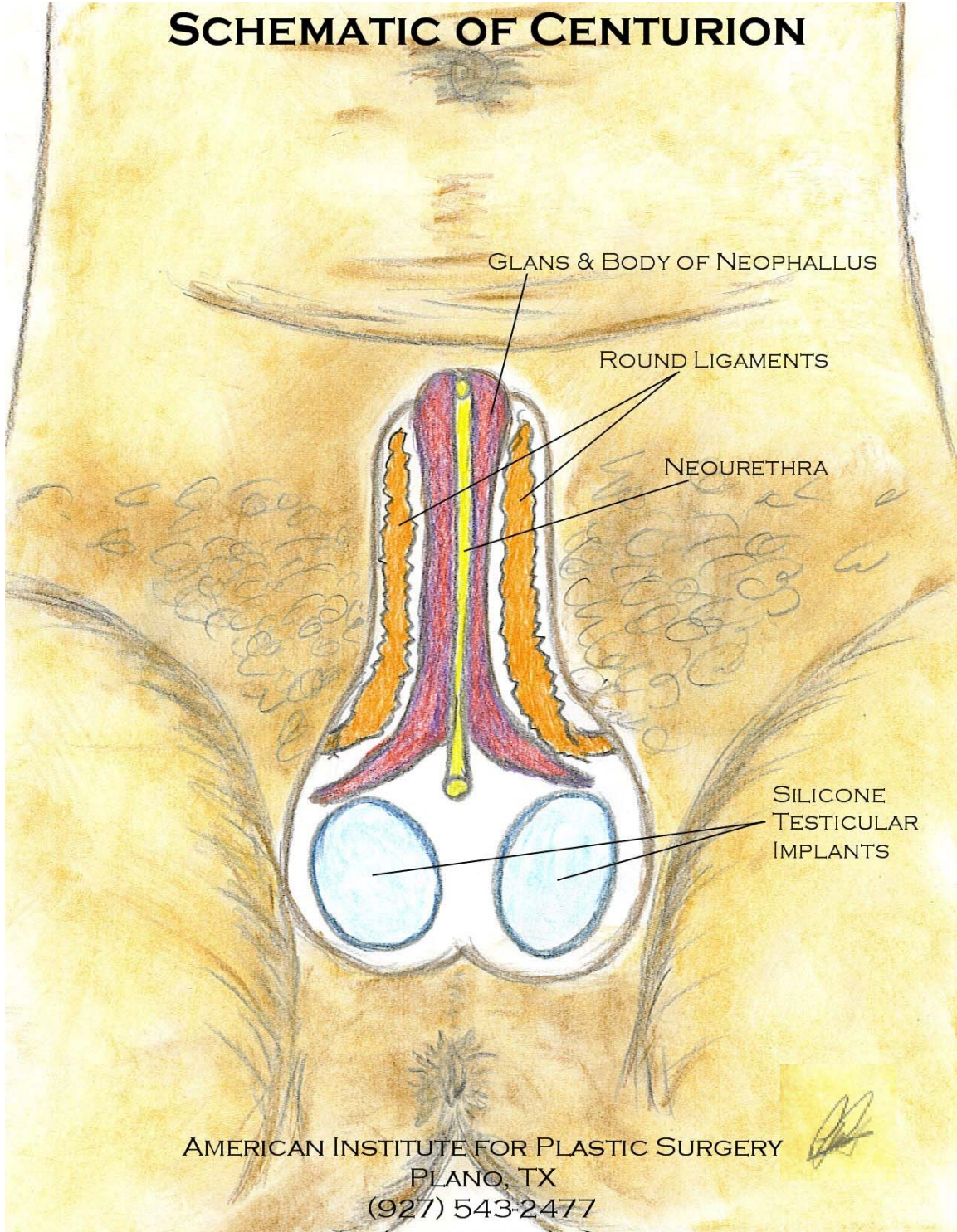
The following two illustrations offer a comparison of the typical metaoidioplasty versus the Centurion and an illustration of the post-operative Centurion. (Because we always protect our patients’ confidentiality, illustrations are used in this article. No actual photographs may be used to educate the public unless informed consent is obtained in a specific release that permits us to use pre-, intra- and post-operative pictures for such purposes. Anyone desiring to have picture of their surgery posted in this or any of our articles for the general public—specifically the pre-op clitoris and the post-op neo-phallus only, no faces, tattoos, etc., should make this known either before surgery and during their pos-op visit when they can view the photos.)



As illustrated above, one of the advantages of the Centurion is that it provides more girth to the neo-phallus. The presence of the round ligaments also adds an additional layer of support and insulation to the neo-urethra that mimics the anatomy of the native male penis.

The illustration below provides a post-operative view of the Centurion.

SCHEMATIC OF CENTURION



Impacting Recovery

Many things can impact a patient's recovery, regardless of the type of surgery, but the primary factors are each patient's health and level of fitness. These are different aspects but both are affected by patient habits and practices and both in turn will provide a positive or negative impact on post-operative recovery.

Obviously obesity and poor diet impact recovery in a negative way. They increase the burden on the body to function and force the body to divert the limited resources a poor diet provides to dealing with functioning under an increased "load" on the system in the case of overweight or obese patients. These factors can impair circulation and the quality of the blood and the nutrients it provides for cellular/tissue recovery.

The habit that most profoundly and negatively affects recovery is tobacco abuse. Cigarettes contain nicotine, which is a proven vasoconstrictor, depressant, and a toxin. While most people associate lung cancer with smoking, nicotine has effects on all parts of the body. Because the Centurion procedure involves a small, critical area and a number of tissue flaps, circulation is crucial to recovery, function, and simply avoiding infection. Nicotine as a vasoconstrictor constricts, or "shrinks down," the blood vessels and in an area with small capillaries of a tiny diameter, any constriction can prove detrimental. As a depressant, nicotine depresses all natural functions in the human body, including the immune system. Combine these with the fact that nicotine is a toxin that the body will expend energy on to combat, and the risk for complications grows exponentially.

The goal of all patients should be to be as physically prepared as they are mentally for the FTM change. Those in the best physical condition will afford themselves the best opportunity for successful recovery and optimal function. While there are no guarantees, no one should ever make the mistake of limiting their options by continuing habits or practices that are harmful or cause the body to divert energy and attention from healing and function to things that are easily avoidable.

The staff and Dr. Raphael will be happy to answer any questions. You can be assured that your questions and concerns will be handled in a timely manner with the utmost confidentiality from the initial discussion to long after your surgery.

This article may not be reproduced or used for general dissemination, whether via hardcopy, email, or website posting, without the expressed consent of the author and the American Institute for Plastic Surgery. ~~ This is necessary to ensure that as the procedure evolves and information is updated to reflect those procedural changes and results, that the most current information is provided to the public. ~~ This will allow the author to maintain a database of users and to notify those individuals, webmasters, etc. of all updates in order to avoid providing any old or misinformation to the public.

You may contact the author via email at drtexmcfaden@sbcglobal.net or by calling directly, at the American Institute for Plastic Surgery in Plano, Texas, at (972) 543-2481.

About the author: Dr. Tex McFaden, a 2001 graduate from the Pikeville College School of Osteopathic Medicine in Pikeville, Kentucky, coordinates the research and clinical trials conducted by Drs. Peter Raphael and Scott Harris at the Institute. He also develops media presentations for professionals and patients, maintains the surgical databases, including the Centurions, and makes the up-to-date Centurion information, such as this article, available for everyone who desires to know more.

Dr. McFaden has a broad background of experience including a B.A. in English/Writing from N.C. State University, is a published author, has served in the U.S. Army, including the Persian Gulf War from 1990-91, and has extensive training and personal experience in nutrition, personal/fitness/strength training, bodybuilding, and powerlifting since 1984.

Dr. McFaden has worked with Dr. Raphael for seven years, including medical school rotations in the 1990's, and surgically assists Dr. Raphael in the operating room on a regular basis. Dr. McFaden has assisted Dr. Raphael on every initial Centurion procedure and any subsequent revisions and serves as the point of contact at the Institute for individuals interested in the Centurion procedure. He assists patients on matters of obtaining information on available FTM procedures, answering subsequent questions regarding the surgery and expenses, scheduling a consultation with Dr. Peter Raphael, and booking the actual surgery.